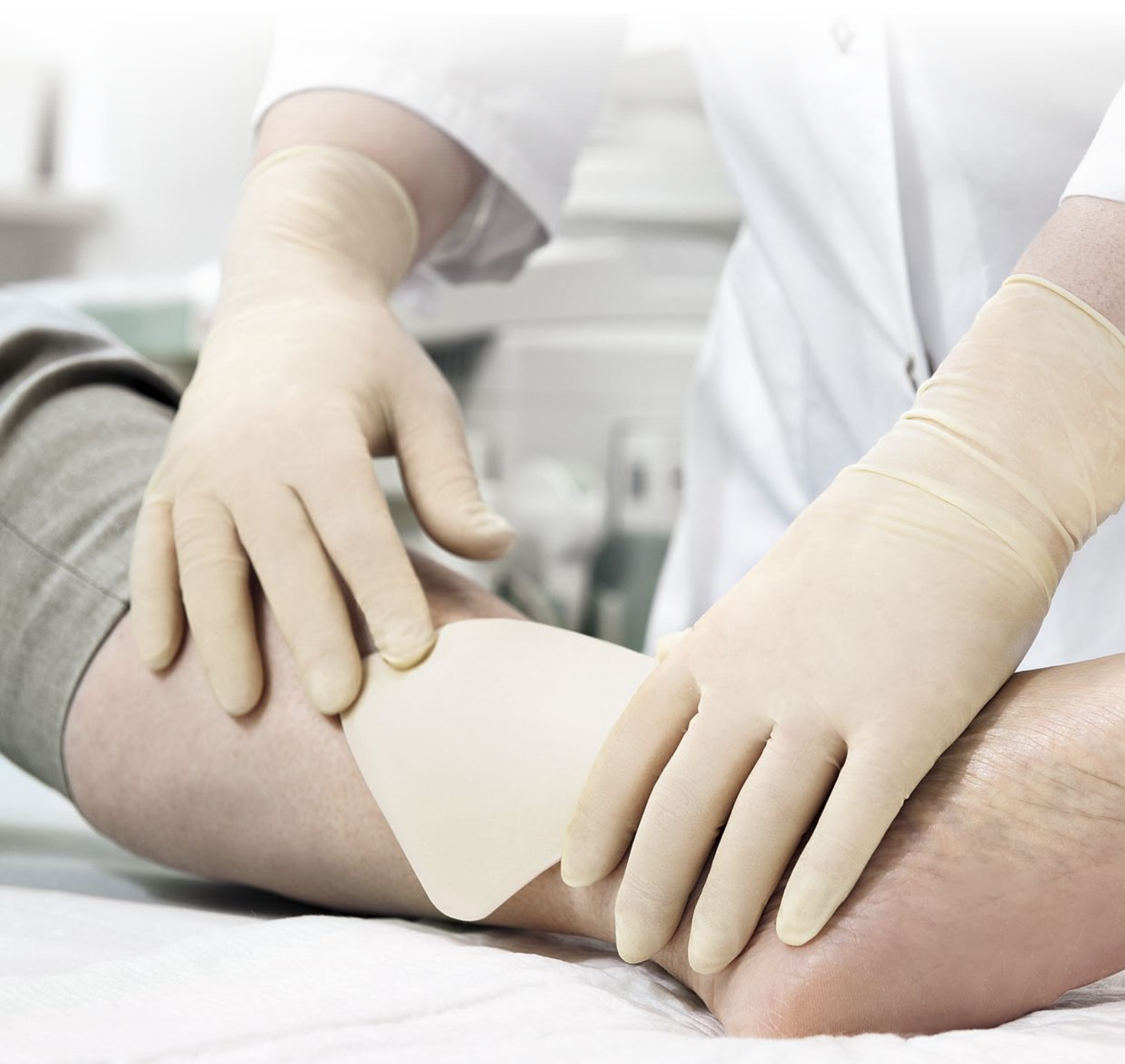



Observational study

Ideal wound environment during granulation and epithelization achieved with HydroTac



Summary

In a multi-centre, observational study the wound healing-promoting effect, tolerability and handling of the foam dressings HydroTac and HydroTac comfort were investigated in the daily routine of hospitals or physician's practices. 270 patients with chronic wounds, such as leg ulcers and decubital ulcers or traumatic wounds and burn wounds were treated. The wounds had persisted for three months on average at the inclusion examination. An improvement in wound status was observed after as little as nine days of treatment, on average. The percentage of epithelial tissue rose from 16 % to 28 % and, at the same time, wound size decreased. Damage to the surrounding skin at the wound sites decreased from 71 % to 46 %.


Overall, therapists and patients were very satisfied with the treatment with HydroTac and HydroTac comfort. The treating persons evaluated the overall impression and the product properties in the most cases as very good or good. In addition to good mechanical properties and good skin tolerability, the simple removability and the easy handling in particular came to the fore. Patient acceptance of treatment with HydroTac and HydroTac comfort was also high. More than 90 % of the patients said their overall impression of the treatment with the wound dressings was very good or good. Besides the wearing comfort and tolerability, the reduction in pain in dressing changes played an essential role.

Both dressings, namely HydroTac and HydroTac comfort, were suitable for treating wounds during the study, with the focus being on maintaining a moist wound environment in order to aid granulation and epithelization.



The wound bed should be sufficiently moist to support cellular processes during the granulation phase. On the other hand, however, wound tissue is not allowed to become damaged by excessive exudate (1). Chronic wounds in particular have been demonstrated to contain inhibitory factors, which attack wound tissue and the wound surroundings, thereby inhibiting healing processes (2-5). A wound dressing has the function of maintaining a moist wound environment, which promotes healing and, at the same, keeps the wound surroundings dry without drying out the wound itself (6).

The absorbent foam dressing HydroTac is particularly coated with hydrogel on the side facing



ing towards the wound, which absorbs wound exudate without drying out the wound. This process is assisted by a semi-permeable film on the side facing away from the wound. The film is permeable to water vapour, so that the absorption capacity of the dressing for exudate is adapted to the wound conditions. Moreover, the film is water and bacteria proof and thus ensures effective protection against contamination. The handling is facilitated by the slight adhesion of the gel layer on the skin because the "Initial Tack" ensures a preliminary fixation. In addition, the dressing does not stick to the wound.

Apart from the standard variant, HydroTac also comes as the self-adhesive variant HydroTac comfort which has been provided with a circumferential adhesive border. Both dressings were tested in an observational study serving to demonstrate their effectiveness, tolerability and handling in clinical practice.

Prospective multi-centre study with 270 patients

The clinical study was conducted at German and French nursing facilities as well as at the practices of registered physicians including general practitioners, dermatologists, surgeons, internal medicine specialists and orthopaedic specialists, all of whom recorded course of treatment over an average of nine days. At inclusion to the study data concerning age, gender and general condition of the patient, age of wound and additional therapeutic measures were collected.

145 of the participating patients were women and 125 men. The average age of the women was 75 years (24 – 98) and the average age of the men was 68 years (31 – 70). In 13 % of the patients, the general condition was very good, in 63 % of the patients, it was appropriate for the age and in 24 % of the patients, it was reduced.

The course of healing was evaluated using a point scale based on various wound condition parameters (coatings, granulation,

Causes of the wounds

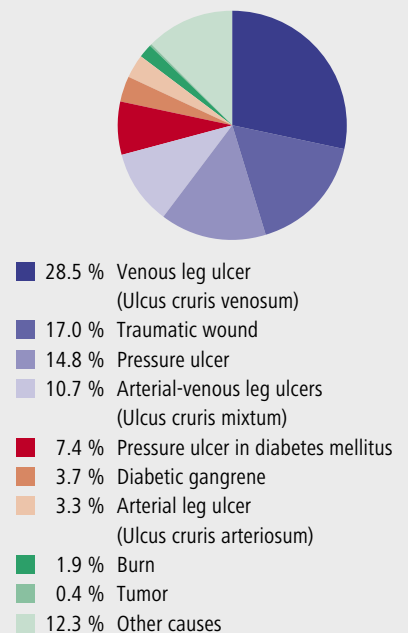


Fig. 1: Aetiology of the treated wounds

infections and pain). At initial and final examination, data concerning the wound surroundings were recorded. Upon completion of examination, the treating physicians evaluated the wound dressing on the basis of its effectiveness, handling and product properties. Patients were asked about tolerability, wearing comfort and pain during treatment with HydroTac and/or HydroTac comfort. In addition to this, the treating persons and patients specified to what extent the product lived up to their expectations.

Almost 70 % of the patients suffered from chronic wounds

The wounds were classified in 28.5 % venous leg ulcer (Ulcus cruris venosum), 3.3 % arterial leg ulcer (Ulcus cruris arteriosum), 10.7 % arterial-venous leg ulcer (Ulcus cruris mixtum), 14.8 % pressure ulcer, 7.4 % pressure ulcer in diabetes mellitus and 3.7 % diabetic gangrene.

Among the non-chronic wounds were 17 % traumatic wounds, 1.9 % resulted from burns and 0.4 % were tumour wounds. 12.2 % had another genesis such as postoperative wounds.

The patients had had their wounds for an average of three months whereby some of the chronic wounds had already been present for many years (up to 20 years).

56 % of the patients were treated with HydroTac and 44 % with HydroTac comfort. Both versions of the product feature the same physical properties, with HydroTac comfort having an additional circumferential adhesive border. To support the treatment, 40 % of the patients received compression treatment and in 25 %, further measures were taken to relieve pressure.

Due to the innovative AquaClear technology HydroTac keeps the wounds sufficiently moist

The gel on the wound-facing side of HydroTac provides the wound with moisture as needed and therefore counteracts the drying out of the wound. A moist wound environment is particularly important during the granulation phase as well as during epithelization, in order to promote cell proliferation and cell migration in the wound bed. Initially, the wounds consisted primarily of granulation tissue, which decreased during the course of treatment, while the percentage of epithelial tissue rose from 16 % to 28 % (Fig. 2a).

As epithelization increased, wound size decreased accordingly during the course of the average nine days of treatment (Fig. 2b).

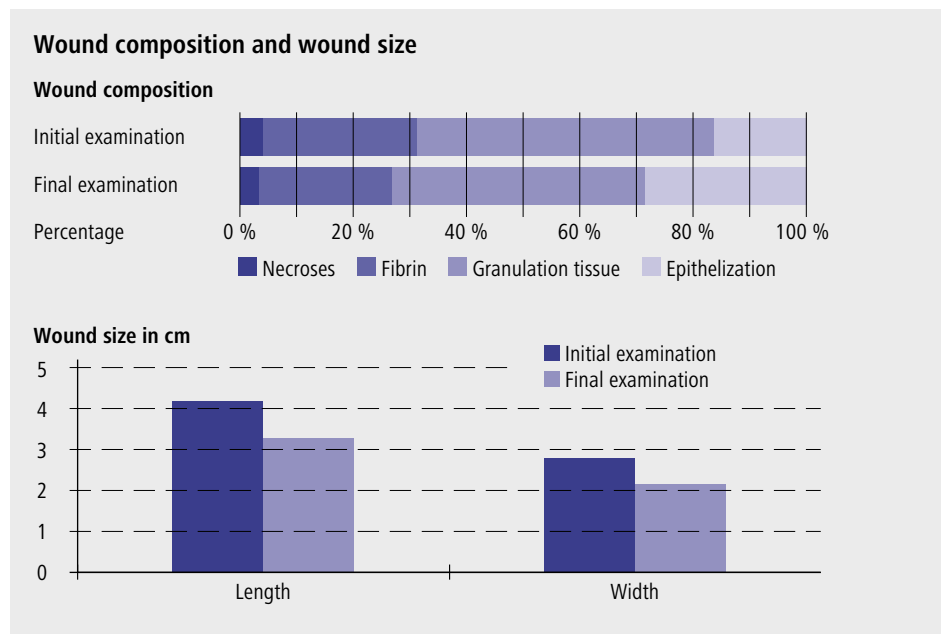


Fig. 2: Whereas the percentage of granulation tissue decreased, epithelization increased. Wound size decreased during the course of the nine days of treatment.

Pain decreased as tissue regeneration increased

Tissue damages cause pain. In the case of slowly healing wounds in particular, a lasting inflammatory reaction can make wounds and surrounding skin more sensitive. Pain decreased (Fig. 3a) during the course of the study as epithelization increased and as the wound surroundings improved (Fig. 5). 65 % of all patients suffered from mild to severe pain at the start of treatment. In contrast to

this, the percentage of patients suffering from pain up to the end of the study decreased by a third to 44 %.

The gel layer made the wound dressing almost painless to remove

The moist gel layer prevented the dressing from sticking to the wound. Only in very rare cases (< 5 %) it was found to stick strongly. However, measures were not needed to carefully remove the wound dressing. Therefore,

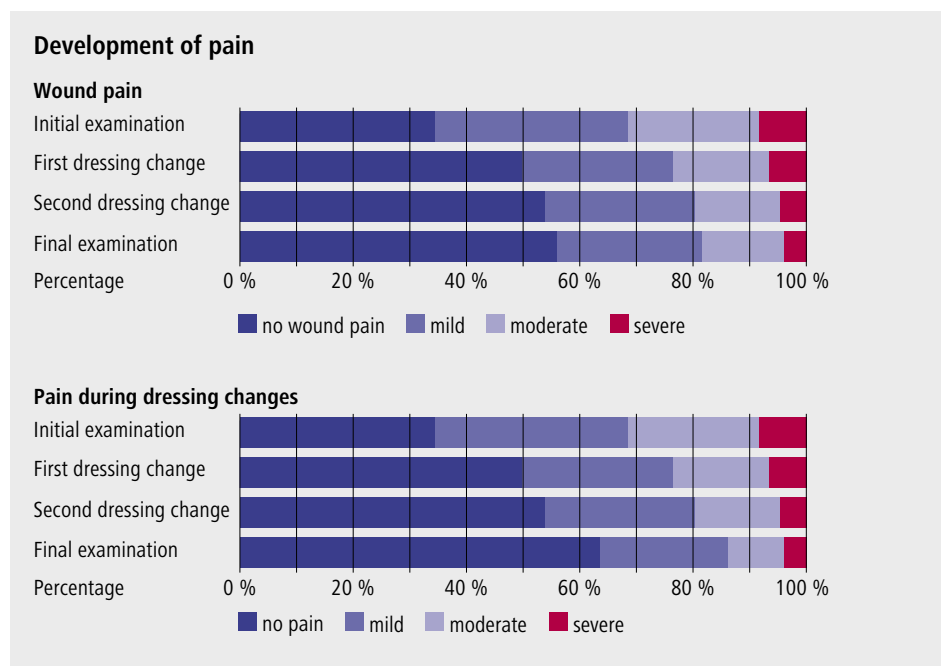
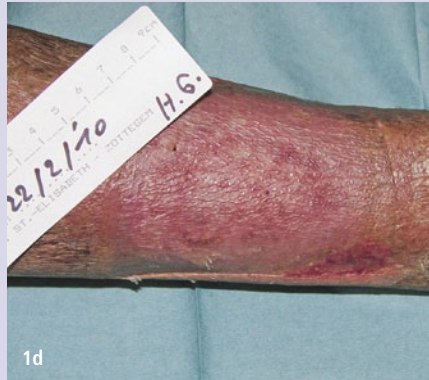
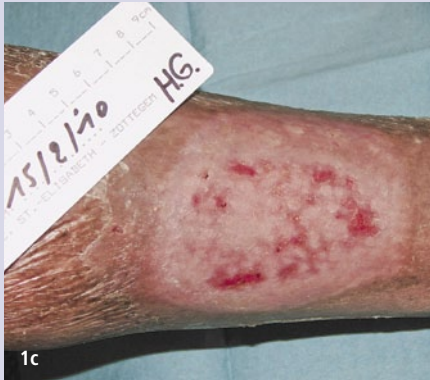
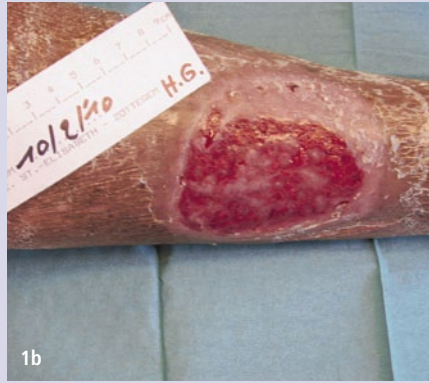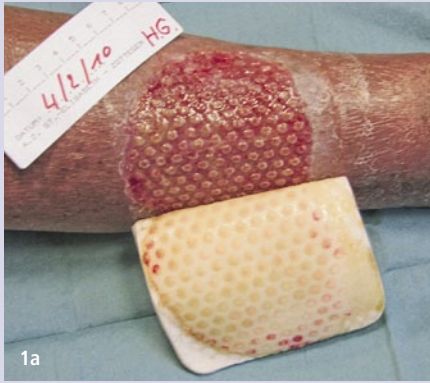Fig. 3: Wound pain decreased during the course of treatment. The percentage of patients, who experienced totally painless dressing changes, increased by the end of treatment.

Fallbeispiele HydroTac



Case example 1: Wound caused by skin blister

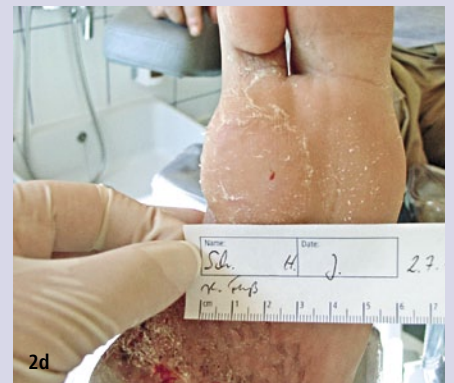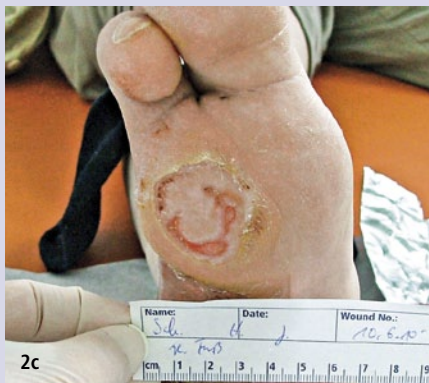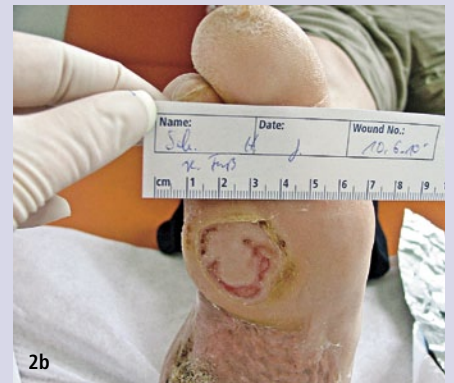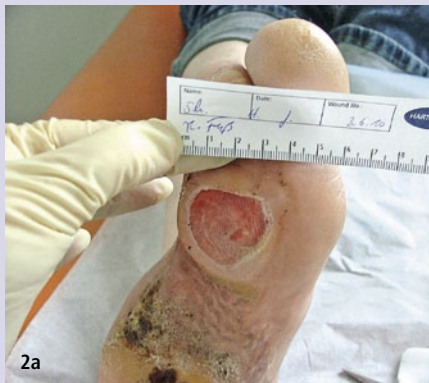77-year old male patient suffering from insulin-dependent diabetes and arterial insufficiency developed a large blister of unknown origin on his right lower leg, which was removed on 4th February 2010. This resulted in a wound surface of 9 x 12 cm, which appeared healthy and showed no signs of infection. Follow-up treatment was carried out with HydroTac, in order to prevent the wound surface from drying out and, at the same time, to absorb wound exudate. The goal was to reach a moist wound environment to promote epithelization. The dressing was changed daily during the first week. Epithelization began rapidly (Fig. 1b). On the 11th day after the start of treatment, the wound surface was already almost completely epithelized (Fig. 1c). One week later, on 22nd February 2010, wound healing was complete, with good cosmetic results having been achieved. The patient was particularly pleased about the painless dressing changes. (Case report: F. Meuleneire, Belgium).

Case example 2: Diabetic ulcer

52-year-old male patient with type 2 diabetes mellitus, metabolic vascular syndrome, adipositas and limited mobility; condition post right foot amputation D 3-5 (cause: original fracture of the right forefoot), moderate depressive episode, Charcot foot in both feet, provided with appropriate footwear.

Following inpatient treatment at an eye clinic, where wound treatment had not been conducted appropriately, the patient trained within the framework of the disease management program came to Dr. Woitek's outpatient foot clinic on 3rd June 2010, admission findings: Fig. 2a.

The diabetic ulcer was treated with HydroTac and additionally padded with the soft protective absorbent dressing pad Zetuvit. The dressing was changed every four days by a nursing service and at the outpatient foot clinic. Only four weeks later, on 2nd July 2010, the diabetic ulcer had healed completely following treatment with HydroTac. (Case report: Dr. Cornelia Woitek, Wurzen, Germany).



Handling

Evaluation of the removability and adhesion ("Initial Tack") of HydroTac and HydroTac comfort by the patients.

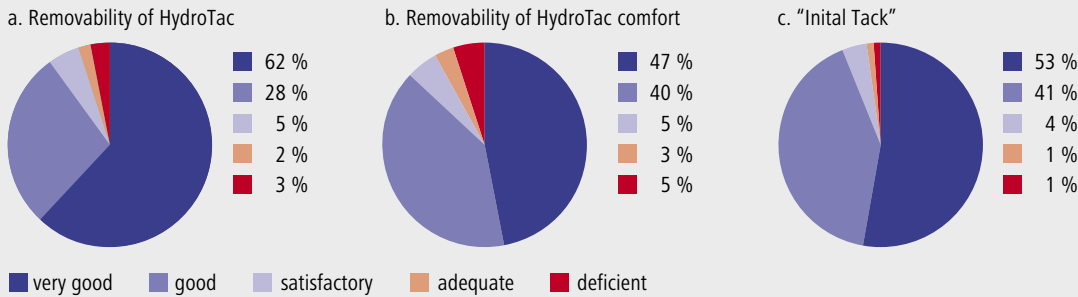


Fig. 4: Due to the hydrogel coating, HydroTac can be removed easily. The good adherence properties of the wound dressing facilitated the handling during dressing changes.

the atraumatic properties of HydroTac ensure the wound rest needed for healing. In 90 % of the cases, the removability of HydroTac was evaluated as good or very good, whereupon 62 % of the patients evaluated the removability as very good.

Despite its additional adhesive border, HydroTac comfort was just as easy to remove. 89 % of patients stated that it was good or very good to remove, with 48 % thereof saying that it was very good to remove (Fig. 4 a/b). All in all, the easy removability also helped to decrease pain during dressing changes. Whereas at the start of the treatment 56 % of the patients had reported mild to severe pain during dressing changes, this was still true in just 36 % of cases at the end of the treatment (Fig. 3b).

Easy handling due to the „Initial Tack“

Despite being easy to remove, the adhesion of the gel layer made dressing changes easier as a consequence of the initial adherence of the wound dressing. 53 % of the users evaluated the easy fixation as very good and 41 % as good (Fig. 4c).

Modulated absorption capacity protects the wound surroundings

Excessive wound exudate leads to damage of the wound margins whereby cell and vessel migration into the wound is impaired. The foam dressing coated with hydrogel absorbs excessive exudate. In addition, the side facing away from the wound adapts, due to the water vapour permeability of its film, the absorption capacity of wound exudate to the wound conditions. Wound margins and wound surroundings were therefore not affected by leaking wound exudate. All in all, skin irritations at wound surroundings decreased from 71 % to 46 %.

All damage present at the start of treatment improved during the course of treatment (Fig. 5).

High degree of acceptance by therapists and patients

The product properties and the handling of HydroTac and HydroTac comfort were highly appreciated by the treating persons (Fig. 6a). The smooth foam featured good draping and cushioning effects and established good contact with the wound base. More than 80 % evaluated these properties as good or very good. The hydrophilic foam material made of polyurethane absorbed excessive exudate effectively and bound it in the inside. The high absorption capacity was assessed in more than 80 % of the cases as good or very good.

Due to the reticulated hydrogel, the wounds were sufficiently provided with moisture. This fact was evaluated in more than 80 % of the cases as good or very good. The wound dressing was well tolerated and provided sufficient protection of the wound margins. 92 % of the treating persons said that their overall impression of the tolerability to the skin of HydroTac and / or HydroTac comfort was good or very good.

The patients were also satisfied with the products (Fig. 6b). 90 % of them evaluated the tolerability and the wearing comfort as good or very good and had altogether a good or very good overall impression of the wound treatment with HydroTac and HydroTac comfort, respectively.

Irritations of the wound surroundings

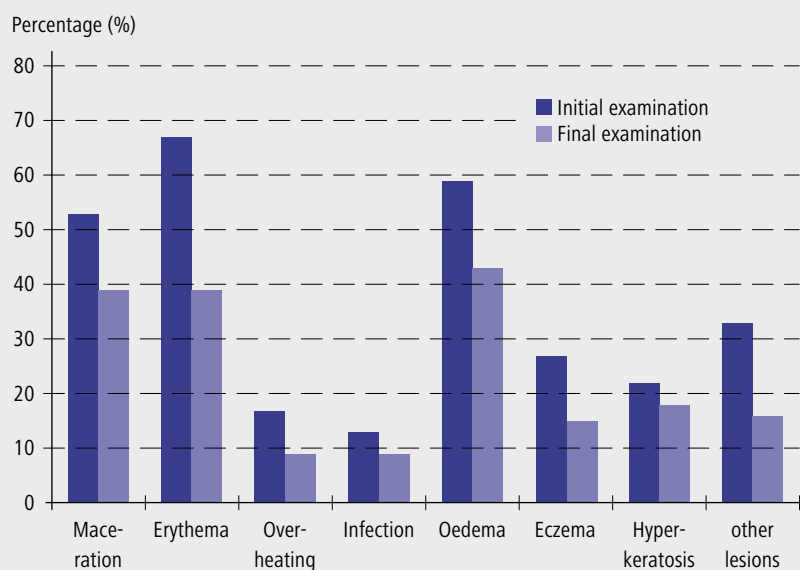
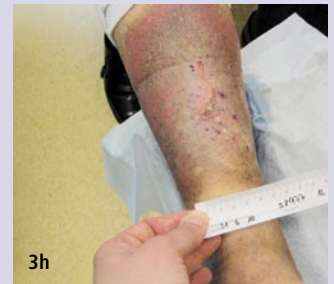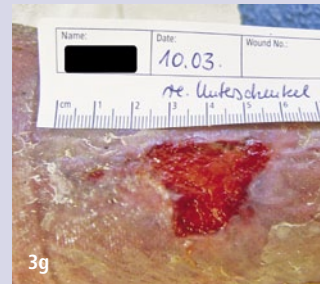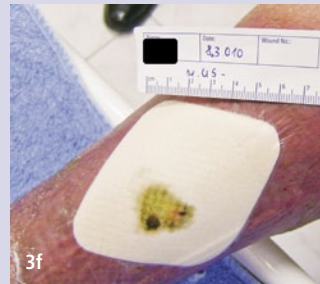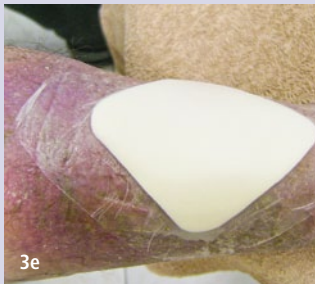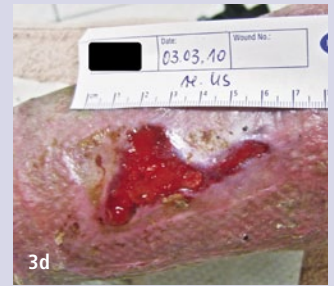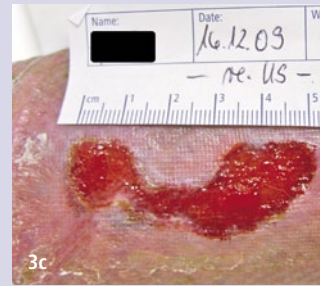


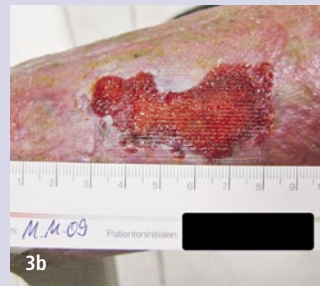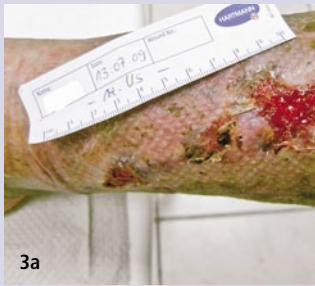Fig. 5: Skin irritations were reduced in the course of the treatment.

Case examples HydroTac



Case example 3: Venous leg ulcer (Ulcus cruris venosum)

75-year-old male patient of normal weight with ulcer on the right lower leg, no leg oedema during the first anamnesis. Initially admitted to hospital in August 2007 because of sepsis. The original site of the sepsis is suspected to be a leg ulcer with positive wound smear, discharged at the end of September. Wound treatment followed using absorbent dressing pads. Readmitted to hospital at the beginning of December 2007, reason: Deterioration of the wound, now the size of an ulcer in the gaiter area. For the first time, chronic venous insufficiency (CVI) is now being considered as the cause. The documentation contains notes that the patient is also suffering from diet controlled type 2 diabetes mellitus and diabetic nephropathy.

At the end of January 2008, surgical treatment in the form of a crossectomy performed as well as stage-adapted stripping of the Vena saphena magna (great saphenous vein), ulcer shaving and subsequent mesh grafting with successful healing. The split-skin graft donor site appears free of irrita-

tions. Wound treatment was to be continued at an outpatient nursing service, which the patient however declines.

At the end of February 2008, the patient's family doctor refers him to a surgical practice. The split-skin graft donor site now appears irritated. A fibrinous ulcer (16 x 11 cm) and necrotic mesh graft (15 x 10 cm) can be seen on the right lower leg. In order to gain control of the excessive and extremely odorous wound exudate, a silver-containing wound dressing and the absorbent dressing pad Zetuvit plus is applied to the wound. The dressing is changed every two days. The patient is now allowing a wound therapist to treat the wound.

The wound situation appears to improve considerably from March 2008 up to July 2009 (Fig. 3a). However, wound healing continually stagnates thereafter. In part, the wound grows again or individual already healed areas break open again. For wound treatment, various types of hydroactive wound dressings are used throughout the whole period of treatment in an attempt to find the right treatment to bring about healing. The compression bandage is now being

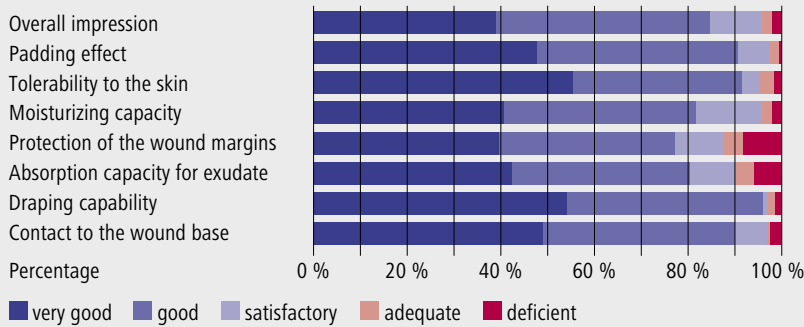
tolerated. The scaly surrounding skin is being cared for.

During wound course, from 13th July 2009 to 11th November 2009, the wound gets progressively smaller in size; however, the wound width remains unchanged. Between 11th November 2009 and 16th December 2009 (Fig. 3c), the wound is seen to have a slow healing tendency. Up to the middle of February 2010, healing stagnates and the wound surroundings become increasingly red.

HydroTac is used for the first time on 3rd March 2010 (Fig. 3d/e). This wound dressing is to be tested using four dressing changes every two days. The saturated wound dressing in Fig. 3f demonstrates that the two-day interval selected is appropriately chosen in this instance. A clear decrease in the size of the wound is evident following the four scheduled dressing changes (Fig. 3g). The patient came for a check-up on 21st June 2010 with closed skin (Fig. 3h). (Case report: Dipl.-Med. R. Mütze, Leipzig, Germany)

Acceptance by therapists and patients

Judgement of the product by the therapists



Judgement of the product by the patients

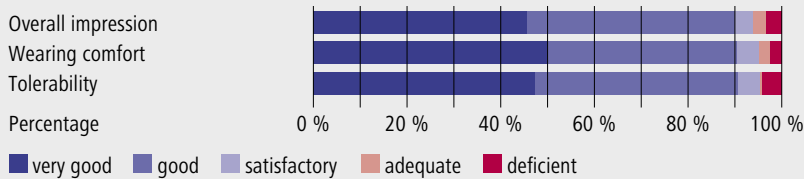


Fig. 6: The therapists evaluated the product properties in the most cases as good or very good. In addition, the patients' degree of acceptance with the easily removable foam dressing was very high.

Product fulfilled the expectations

In 54 % of the patients, the treating persons found that HydroTac and HydroTac comfort fulfilled their expectations and even exceeded their expectations in 15 % of the cases (Fig. 7). In 17 % of the cases, the expectations were mostly fulfilled and in 10 % of the cases the expectations were not really fulfilled and in 4 % of the cases not fulfilled. For 61 % of the cases the patients expectations were fulfilled or exceeded in 13 % of the cases. 11 % of the patients found the expectations mostly fulfilled, 7 % of the patients found them not

really fulfilled, and 8% of the patients found them not fulfilled.

Conclusions

- Maintaining a moist wound environment on the one hand, and a high absorption capacity for excessive wound exudate on the other are essential conditions, which a wound dressing needs to meet in order to facilitate a healing process without complications.
- The absorbent foam and the flexible film backing which is permeable to water va-

pour, together with the moisturising gel layer, provide a balanced level of wound moisture. The treatment of chronic and acute wounds led, within short treatment duration, to an improvement of wounds, which had been present for several years in some instances.

- The easy applicability, due to the "Initial Tack", and painless removability are much valued by both treating persons and patients.
- Both wound dressings – HydroTac and HydroTac comfort – are particularly suitable for the treatment of clean wounds requiring special attention as to moisture regulation.

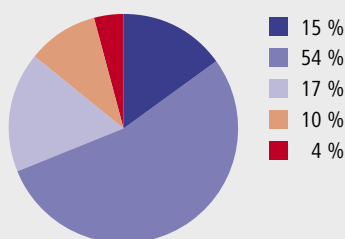
References:

1. Falanga, V. (2000) Classifications for wound bed preparation and stimulation of chronic wounds. *Wound Repair Regen* 8, 347-52
2. Bucalo, B., Eaglstein, W. H. and Falanga, V. (1993) Inhibition of cell proliferation by chronic wound fluid. *Wound Repair Regen* 1, 181-186
3. Tarnuzzer, R. W. and Schultz, G. S. (1996) Biochemical analysis of acute and chronic wound environments. *Wound Repair Regen* 4, 321-325
4. Trengove, N. J., Stacey, M. C., MacAuley, S., Bennett, N., Gibson, J., Burslem, F., Murphy, G. and Schultz, G. (1999) Analysis of the acute and chronic wound environments: the role of proteases and their inhibitors. *Wound Repair Regen* 7, 442-452
5. Trengove, N. J., Bielefeldt-Ohmann, H. and Stacey, M. C. (2000) Mitogenic activity and cytokine levels in non-healing and healing chronic leg ulcers. *Wound Repair Regen* 8, 13-25
6. Sibbald, R. G., Williamson, D., Orsted, H. L., Campbell, K., Keast, D., Krasner, D. and Sibbald, D. (2000) Preparing the wound bed--debridement, bacterial balance, and moisture balance. *Ostomy Wound Manage* 46, 14-22, 24-8, 30-5; quiz

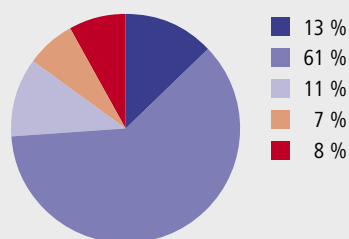
Expectations placed on HydroTac

Expectations placed on the product by the treating person and the patient

Expectations placed on the wound dressing by the treating person



Expectations placed on the wound dressing by the patients



■ exceeded ■ fulfilled ■ mostly fulfilled ■ not really fulfilled ■ not fulfilled

Fig. 7: The expectations of the treating persons and the patients were mostly fulfilled



helps healing.

PAUL HARTMANN AG
89522 Heidenheim
Germany

Visit our Website:
www.hartmann.info